



Guideline for the management of ovarian cysts in children and adolescents

Author list: J.Ritchie, F.O'Mahony, A.Garden

On behalf of British Society for Paediatric & Adolescent Gynaecology

1. PURPOSE OF THE GUIDELINE

The aim of this guideline is to provide guidance for paediatric surgeons and gynaecologists who may be involved in the care of children or adolescents with ovarian cysts, to facilitate the appropriate management.

2. BACKGROUND

Masses in the pelvis, although usually of gynaecologic origin, can also arise from the urinary tract, bowel, or other pelvic structures [1]. Ovarian cysts in children are very common; the vast majority of them are benign and self-resolving, with less than 10% of these cysts being malignant [1]. Ovarian malignant tumours account for only 1% of all childhood cancers [2].

Ovarian cysts are the most common cause of abdominal cystic lesions in female fetuses and neonates. They are usually diagnosed in the third trimester, and they can be of varying size. The vast majority are unilateral and simple in nature. The aetiology is fetal gonadotrophins, maternal oestrogen or placental HCG. Complications of antenatal/neonatal ovarian cysts include rupture, torsion, haemorrhage and compression on nearby structures. The vast majority will regress spontaneously but this can take several months.

The frequency of follicular cysts decreases throughout childhood, and then increases again with puberty. Endocrine conditions such as precocious puberty, hypothyroidism and aromatase deficiency can be associated with ovarian cysts. Hormone-secreting ovarian cysts can result in recurrent vaginal bleeding suggesting McCune-Albright Syndrome.

While there is a RCOG guideline for ovarian cysts in premenopausal women [3], there are no clear guidelines on the management of ovarian cysts in children; this appears to have led to over treatment of benign ovarian cysts, with multiple follow up scans and often unnecessary surgery. The management of ovarian cysts in children and adolescents should include the participation of gynaecologist with a specialist knowledge of paediatric and adolescent gynaecology (PAG) to reduce the over treatment of benign ovarian cysts which

may resolve spontaneously. Paediatric surgeons will usually undertake surgery for the younger girls, however for older girls (age dependent on the specific hospital guidelines and facilities), surgery for ovarian cysts should be carried out by a gynaecologist with the appropriate surgical skills to reduce the need for an unnecessary laparotomy, removal of healthy ovarian tissue or oophorectomy. Ovarian Torsion is one of the only indications for immediate surgery and any other pathology can usually be managed in collaboration with a PAG specialist.

3. RECOGNITION AND ASSESSMENT

3.1 Definition

A cyst is a fluid filled sac which is greater than 3cm, and so a 'cyst' which is less than 3cm should not be classified as a cyst, it is a normal physiological finding. In pre-pubertal girls, follicular activity may be seen but the follicles are usually less than 10mm in diameter.

Ovarian cysts can be simple or complex.

A **simple** ovarian cyst is one which is unilocular and fluid filled, with no septations, solid areas or other features.

A **complex** cyst can be multilocular and may contain haemorrhage, septations or solid areas.

3.2 Symptoms and Signs

Many simple ovarian cysts are asymptomatic and only identified incidentally on ultrasound.

Larger ovarian cysts can cause pain and pressure symptoms. Torsion of a cyst will usually cause severe pain and present as an acute abdomen. In prepubescent girls, an ovarian torsion can occur without associated adnexal pathology.

3.3 Investigations

Ultrasound (USS) is the initial radiological investigation of choice preferably performed by a radiologist or radiographer with experience of paediatric gynaecological imaging. This should be done trans-abdominally in girls who have not been sexually active. Some clinicians might also offer transrectal route as alternative to transvaginal route of scanning which is the preferred route if the patient is sexually active.

Further investigations depend on the size and nature of the cyst.

In the acute setting, for example if an ovarian torsion is clinically suspected then the patient may need to go to theatre prior to further investigations. An USS in a pre-pubescent ovarian torsion will often show peripherally arranged follicles in addition to ovarian enlargement and oedema [4].

In the non-acute setting, If the child/young woman has achieved menarche then the following investigations apply [3, 5]

If the cyst is complex or there are any suspicious features, germ cell tumour markers (HCG, AFP, LDH) and CA125 should be performed. An MRI may also be considered.

If an ovarian cyst is found in a pre-pubertal girl, a hormone profile (including FSH, LH, Oestradiol and thyroid function) should be considered especially if there are any signs of precocious puberty.

Table: Investigations for ovarian cysts in adolescents

Simple cyst <5cm	Simple cyst 5-7cm	Simple cyst >7cm	Complex cyst
Follow up scan in 3 months for reassurance and to confirm resolution of cyst	Follow up scan in 3 months to check for resolution or ensure not increasing in size.	Offer laparoscopic ovarian cystectomy or surveillance ultrasound in 3 months	<p>Bloods</p> <ul style="list-style-type: none"> ➤ Lactate Dehydrogenase (LDH) ➤ Human Chorionic Gonadotrophin (HCG) ➤ Alpha-fetoprotein (AFP) ➤ CA125 <p>Imaging</p> <ul style="list-style-type: none"> ➤ If haemorrhagic cyst suspected, repeat USS in 6-8 weeks to confirm resolution. ➤ If dermoid cyst suspected, follow up with surveillance scan in 3-4 months or offer laparoscopic ovarian cystectomy if >5cm. ➤ If suspicious features, or unsure re pathology, consider MRI

3.4 Differential Diagnosis

Simple cysts are most often a normal physiological finding which occurs due to the menstrual cycle. If no egg is released from a developing follicle, the fluid stays in the follicle and forms a cyst. This is called a follicular cyst. If the egg has been released a corpus luteum cyst can form. This type of cyst often contains a small amount of blood. Some simple cysts on ultrasound are parafimbrial, paratubal or broad ligament cysts rather than ovarian, and these can be quite large.

Complex cysts can be either benign or malignant. Common examples include:

Benign

- Endometrioma

Pelvic mass arising from growth of ectopic endometrial tissue within the ovary, typically contain thick brown fluid, commonly referred to as a chocolate cyst.

Pain is usually cyclical and may be associated with dysmenorrhea and dyspareunia (if sexually active).

- Dermoid (Mature cystic teratoma)

These are the most common benign tumours in children and adolescents. They tend to grow slowly and contain mature tissue. They can frequently contain clumps of hair, pockets of sebum, blood, fat, bone, nails, teeth, eyes, cartilage, and thyroid tissue. They have a classical appearance on ultrasound and MRI.

- Haemorrhagic cyst

These usually result from haemorrhage into a corpus luteum or other functional cyst. Radiographic features are variable depending on the age of the haemorrhage, and may mimic an endometrioma. A rescan will often eliminate confusion as a haemorrhagic cyst will usually resolve over a 2-3 cycles, but endometrioma usually will not resolve in the absence of treatment.

Malignant

Germ cell tumors are the most common malignancy

- Dysgerminoma
- Endodermal sinus tumour (usually associated with a rise in AFP)
- Embryonal carcinoma
- Choriocarcinoma (associated with a rise in hCG)

4. **MANAGEMENT**

4.1 **Conservative**

A conservative approach is appropriate for asymptomatic simple ovarian cysts which are <7cm; these can be followed up with surveillance USS (see table) [3] and the patient should be referred to the PAG clinic to review the follow up ultrasound scan and organise on-going management.

Most large ovarian cysts in children (simple or complex) may be safely followed with serial pelvic ultrasonography, because most cysts will either decrease in size or resolve. Neither the character of the cyst nor the size reliably predicts clinical outcome [6].

Cysts that persist or increase in size are unlikely to be functional and may warrant surgical management and the patient should be referred to the paediatric and adolescent gynaecology clinic to decide upon further management.

Management of an antenatal/neonatal simple cyst is usually conservative with serial scans. If the cyst is very large (?? what size), or torsion is suspected, then laparoscopic drainage may be performed. This should be performed by paediatric surgeons.

In the absence of precocious puberty, simple cysts in pre-pubertal girls should be managed conservatively as the majority will regress spontaneously. If there are any concerns about endocrine disorders, the girl should, be managed jointly with a paediatric endocrinologist.

Surgery

There is no evidence-based consensus on the size of an ovarian cyst above which surgical management should be considered. Most studies done in premenopausal women have used an arbitrary maximum diameter of 50–60 mm among their inclusion criteria to offer conservative management [3]

The management of all adolescents with an ovarian cyst should ideally be discussed with the gynaecology team prior to any surgical management. If an ovarian cyst is identified incidentally at the time of non-gynaecological surgery, a gynaecologist should be called before embarking on any surgery on the ovarian cyst. A paediatric surgeon should also be involved for younger children. If malignancy is suspected, the case should be discussed in gynaecological or paediatric oncology multidisciplinary team.

Laparoscopic surgery as opposed to a laparotomy will reduce post-operative pain, length of hospital stay and reduce the chance of adhesions, and should therefore be the preferred route of surgery if possible [4].

Whatever type of surgery is performed all attempts should be made to save the ovary and perform a cystectomy rather than an oophorectomy. In children preservation of as much ovarian tissue as possible is especially important for pubertal development as well as for future fertility.

Cystectomy is the operation of choice as drainage is associated with a high chance of recurrence and is therefore not recommended [4]. This is especially important for endometrioma as cystectomy has been showed to be to reduce the chance of recurrence of the endometrioma and also the recurrence of pelvic pain compared to drainage [7]. The management of endometrioma is best done in association with endometriosis centre [7].

Laparoscopic cystectomy is also the treatment of choice for dermoid cysts/teratoma to preserve ovarian functions. Any inadvertent spillage should be efficiently cleared up with thorough irrigation and suction, with careful attention to ensure the paracolic gutters are clean and free of spillage. The risk of chemical peritonitis is less than 1% [8].

Teratoma/ dermoid cysts and endometriomata are conditions which may be bilateral so preservation of ovarian tissue is essential in case they present in the future with a subsequent cyst on their contralateral ovary.

In ovarian torsion every effort should be made to save the ovary by untwisting the ovary and draining any cysts. A consultant with the relevant expertise should be involved. Even if the ovary appears black and necrotic in most cases the ovary will usually recover and result in a functional ovary [9]. Cystectomy would be difficult in this situation due to the fragile tissues and can be carried out at an interval operation if required. Oophoropexy remains controversial with limited long term data and is generally not recommended [4].

5. FOLLOW UP

All children and adolescents who are either diagnosed with an ovarian cyst or who have surgical management of an ovarian cyst can be seen in the PAG clinic even if it has not been possible for her to have been seen by a gynaecologist pre-operatively. This is to ensure the correct management is followed and allow counselling to the girl with regards to future fertility.

6. IN SUMMARY

1. Management of ovarian cysts in children and adolescents should ideally include participation of a gynaecologist with a specialist knowledge of PAG to try and reduce the over treatment of benign ovarian cysts which may resolve spontaneously.
2. Any surgery for ovarian cysts should be carried out by a gynaecologist/paediatric surgeon with the appropriate surgical skills to reduce the need for an unnecessary laparotomy or oophorectomy.
3. All complex cysts should have tumour markers taken to rule out germ cell tumours.
4. If an ovarian cyst is discovered incidentally at the time of surgery by a non-gynaecology speciality, it is preferable to discuss with the gynaecology

team before commencing any intervention to the ovarian cyst as it might not be needed.

Acknowledgements:

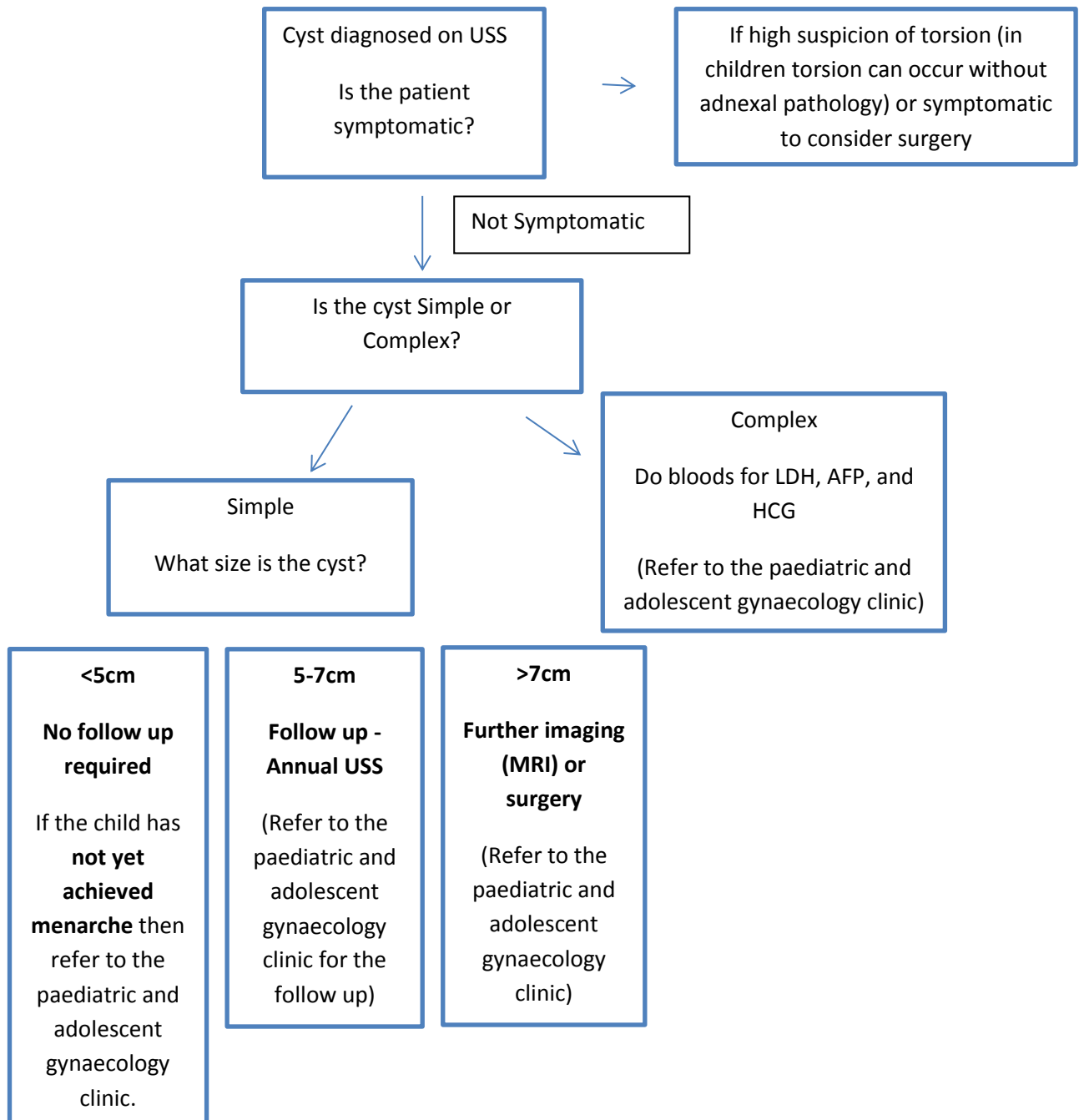
Authors- Dr J.Ritchie , Miss F.O'Mahony, Professor A.Garden

The BRITSPAG executive committee commented on the draft guidance and then it was finalised.

References

1. Laufer MR. Adnexal masses. In: Emans, Laufer, & Goldstein's Pediatric and Adolescent Gynecology, 6th ed, Emans JE, Laufer MR (Eds), Lippincott Williams & Wilkins, Philadelphia 2012. p.381.
2. Kozlowski KJ. Ovarian masses. *Adolesc Med.* 1999;10(2):337-350
3. Ovarian Masses in Premenopausal Women, Management of Suspected (Green-top Guideline No. 62), RCOG 2011
4. Damigos E, Johns J, Ross J. An update on the diagnosis and management of ovarian torsion. *The Obstetrician & Gynaecologist* 2012;14: 229–236
5. Andres MM, Costa E, Canete A, Moreno L, Castel V. Solid ovarian tumours in childhood: A 35 year review in a single institution. *Clin Transl Oncol* 2010;12:287-91
6. Warner BW, Kuhn JC, Barr LL. Conservative management of large ovarian cysts in children: the value of serial pelvic ultrasonography. *Surgery* 1992; 112:749
7. NICE guideline on management of women with endometriosis NG 73: September 2017
8. Nezhat CR, Kalyoncu S, Nezhat CH, Johnson E, Berlanda N, Nezhat F. Laparoscopic management of ovarian dermoid cyst: ten years' experience. *JSLs.* 1999; 3: 179–184
9. Oelsner G, Bider D, Goldenberg M, Admon D, Mashiach S. Long-term follow-up of the twisted ischaemic adnexal mass managed by detorsion. *Fertil Steril* 1993; 60:976–9.

Appendix: Flow chart for cysts diagnosed on an Ultrasound scan.



For cysts diagnosed at the time of surgery

If an ovarian cyst is discovered incidentally at the time of surgery by a non-gynaecology speciality please seek advice from the gynaecology team before commencing any intervention on the ovarian cyst.